

Chapter 4

Secondary chronic venous disorders

Mark H. Meissner, MD,^a Bo Eklof, MD,^b Phillip Coleridge Smith, MD,^c Michael C. Dalsing, MD,^d Ralph G. DePalma, MD,^e Peter Gloviczki, MD,^f Gregory Moneta, MD,^g Peter Neglén, MD,^h Thomas O' Donnell, MD,ⁱ Hugo Partsch, MD,^j and Seshadri Raju, MD,^h *Seattle, Wash; Honolulu, HI; Helsingborg, Sweden; London, United Kingdom; Indianapolis, Ind; Washington DC; Rochester, Minn; Portland, Ore; Flowood, Miss; Boston, Mass; and Vienna, Austria*

Secondary chronic venous disorders (CVD) usually follow an episode of acute deep venous thrombosis (DVT). Most occluded venous segments recanalize over the first 6 to 12 months after an episode of acute DVT, leading to chronic luminal changes and a combination of partial obstruction and reflux. Such morphological changes produce venous hypertension with the highest levels of ambulatory venous pressure occurring in patients with combined outflow obstruction and distal reflux. The clinical manifestations of secondary CVD, including pain, venous claudication, edema, skin changes, and ulceration are commonly referred to as the post-thrombotic syndrome. Such sequelae are best avoided by early and aggressive treatment of proximal DVT.

The diagnostic evaluation of secondary CVD is similar to primary CVD and is based upon duplex ultrasound. However, the definition of hemodynamically significant venous stenosis remains obscure and there are no reliable tests to confirm the presence of such lesions. Diagnosis depends more on anatomic rather than hemodynamic criteria, and IVUS is superior to venography in estimating the morphological degree and extent of iliac vein stenosis.

The fundamental role of compression in the treatment of CVD is well recognized. Compliance with compression is essential to heal ulcers and minimize recurrence. The efficacy of various adjuncts to ulcer treatment, including complex wound dressings and medications have been variable. Although superficial venous surgery has not been demonstrated to improve ulcer healing rates, it does decrease ulcer recurrence. Deep venous valve reconstruction is performed in only a few specialized centers, and the results are better for primary than for secondary CVD. Treatment of incompetent perforating veins remains controversial. Although artificial venous valves are promising, most early experimental models have failed. With respect to venous obstruction, ilio caval angioplasty and stenting has emerged as the primary treatment for proximal iliofemoral venous obstruction with surgical bypass assuming a secondary role. (*J Vasc Surg* 2007;46:68S-83S.)

INTRODUCTION

The manifestations of chronic venous insufficiency may be either primary or secondary in etiology. Primary venous disorders are not associated with identifiable etiologic mechanisms of venous dysfunction. In contrast, secondary venous disorders result from an antecedent event, usually an episode of acute deep venous thrombosis (DVT). Although reflux alone is responsible for primary chronic venous insufficiency (CVI), secondary CVI most often results from a combination of obstruction and reflux. When developing after an episode of DVT, manifestations of pain, edema,

skin changes and ulceration are commonly referred to as the post-thrombotic syndrome.

Cutaneous ulceration due to CVI has been known for over three and a half millennia. Aesculapius established care centers as early as 1500 BC; although he treated venous ulcers successfully, the details were largely ignored.¹ In 400BC, Hippocrates, who himself had a leg ulcer, said, "In the case of an ulcer, it is not expedient to stand, especially if the ulcer be situated on the leg."² Compression was used throughout the middle ages, and later by Richard Wiseman, the 17th century Sergeant Surgeon to Charles II.³ John Gay pointed out in 1866 that skin changes and leg ulcers were associated with post-thrombotic disease of the deep veins. This concept was reiterated by Homans who underlined the importance of venous stasis.

The Swedish phlebologist Gunnar Bauer first recognized destruction of the deep venous valves as the cause of post-thrombotic disease. Using descending transfemoral venography, Bauer showed that most deep veins recanalized after DVT and that the valves were destroyed during this process. He differentiated these findings from those of primary CVI, noting that deep venous reflux identified on descending venography was not caused by previous throm-

From the Department of Surgery, University of Washington School of Medicine^a; Straub Foundation^b; University College London Medical School^c; Indiana University Medical School^d; Department of Veteran's Affairs^e; Mayo Clinic^f; Oregon Health Sciences University^g; River Oaks Hospital^h; New England Medical Centerⁱ; and Department of Dermatology, University of Vienna^l.

Competition of interest: none

Correspondence: Mark H. Meissner, MD, Department of Surgery, Box 356410, University of Washington Medical Center, 1589 NE Pacific Street, Seattle, WA 98195 (e-mail: meissner@u.washington.edu).

0741-5214/\$32.00

Copyright © 2007 by The Society for Vascular Surgery.

doi:10.1016/j.jvs.2007.08.048

bosis in 30 of 55 limbs.⁴ Based on his studies of heparin for the prevention and treatment of DVT, Bauer's suggested that the best way to avoid the post-thrombotic syndrome was by immediate and aggressive treatment of acute thrombosis.

Once developed, venous leg ulcers are often a disabling condition with significant chronicity. Nearly one half of affected limbs suffer a recurrence within a decade. The direct costs of ulcer treatment have been estimated to be \$2500 per month in the United States and approximately 1% of the national healthcare budget in other industrialized countries.⁵ Any treatment modality that increases the proportion of healed ulcers and speeds the rate of healing will both reduce cost and decrease patient suffering.

DIAGNOSIS OF SECONDARY CHRONIC VENOUS INSUFFICIENCY

Treatment should always be directed towards improving pathophysiology and, as described in the diagnosis and hemodynamics section of this supplement, characterization of the underlying anatomy and physiology is crucial for successful therapy. Although the trophic and ulcerative changes at the ankle may be identical, the underlying pathophysiology and anatomy may be vastly different between limbs.⁶ The pathophysiology is often complex, with a combination of venous reflux and obstruction, endothelial dysfunction, deranged lymphatic function, and associated arterial occlusive disease, joint disorders, metabolic disturbances, and other pathology contributing to the clinical presentation. About 30% of leg ulcers are not of venous origin and a "venous leg ulcer" should only be diagnosed if major venous disturbances are both clearly demonstrated and primarily responsible for the clinical presentation.

The history and clinical features are often misleading and may not differentiate venous ulcers from other etiologies. The differential diagnosis must include arterial occlusive disease; small vessel diseases such as vasculitis; hematological disorders like spherocytosis, sickle cell anemia, cryoglobulinemia, and thrombocytosis; traumatic and self-inflicted ulcers; ulcerated tumors like basal cell carcinoma; infections caused by acid fast bacilli (Buruli-ulcer), fungi, or protozoa; neuropathic ulcers; and others, like pyoderma gangrenosum. The diagnosis in such cases can only be made by specialized testing that may include bacteriologic investigation and biopsies. Although it is not clear if they are causative or an epiphenomenon, coagulation defects have been described in 41% of patients with leg ulcers.⁷ However, this finding does suggest that many patients with venous leg ulcers have unsuspected post-thrombotic disease.

Evaluation of the patient with a suspected venous leg ulcer should include duplex ultrasonography to identify reflux in the superficial, deep, and perforating veins as well as obstruction of the deep veins. Plethysmography, venous pressure measurement, and venography may also be useful, especially in patients being considered for surgery. Any detected pathology should be classified using the CEAP classification, which may guide further therapy.⁸ Measure-

ment of the ankle-brachial index (ABI) by Doppler ultrasonography is essential in excluding arterial occlusive disease, which may be present in 20% of patients and is required before initiating compression therapy. In measuring the ankle pressure, the cuff should be placed on the distal leg, even when there are ulcers in the region, and not over the calf as occasionally recommended.

Early diagnosis and treatment is essential to rapid ulcer healing. Lack of improvement over a 4-week period requires re-evaluation of the diagnosis and consideration of a biopsy to exclude either an ulcerated malignancy or malignant transformation of the ulcer.

NONOPERATIVE TREATMENT OF CHRONIC VENOUS INSUFFICIENCY

General recommendations

General measures in the treatment of chronic venous insufficiency include leg elevation, which reduces venous hypertension. Weight reduction, walking exercise, and physical therapy to improve ankle joint mobility may also be important. Systemic conditions affecting wound healing and edema (diabetes mellitus, immunosuppression, malnutrition, congestive heart failure) should be optimally managed.

Compression therapy

The fundamental role of compression in the treatment of chronic venous insufficiency is well recognized and has been validated by randomized controlled trials (RCTs).^{9,10} Compression can be achieved with a variety of techniques and devices and is sufficient to heal the majority of venous ulcers. Healing, however, can be prolonged and ulcer recurrence remains a major problem. Patients must understand that they have a chronic disease that can be managed but not necessarily cured. Compliance with treatment is essential to heal ulcers and minimize recurrence.¹¹

The presence of chronic venous disease must be definitively established prior to beginning compression therapy. Arterial occlusive disease is a contraindication to conventional high-pressure compression treatment. This is especially true for patients with an ABI < 0.5 and with the use of elastic, long stretch material. However, inelastic bandages, applied with a resting pressure of less than 20 mm Hg and used in conjunction with active exercise, will reduce edema and increase arterial flow similar to the use of intermittent pneumatic compression.¹²

The exact mechanism by which compression improves the symptoms of CVI and heals ulceration is unknown. Although most experimental studies have been performed using insufficient compression, high-pressure bandages do reduce venous reflux and improve calf muscle pump function.¹³⁻¹⁵ Improvements in skin and subcutaneous microcirculation and direct effects on subcutaneous pressure have also been hypothesized. A compression induced increase in subcutaneous tissue pressure may counteract transcapillary Starling forces, thereby decreasing edema.^{16,17} Edema reduction may also improve local metabolism by enhancing

Table I. Indications for medical compression stockings

Indication	Compression pressure (mm Hg)				Duration
	10-20	20-30	30-40	≥40	
	<i>Chronic venous disorders</i>				
C0s	1 st choice	If necessary			Symptomatic
C1s	1 st choice	If necessary			Symptomatic
C2	1 st choice	If necessary			Symptomatic
C3	If possible	1 st choice	If necessary		Symptomatic
C4		1 st choice	If necessary		Routine
C5		If possible	1 st choice	If necessary	Always in deep CVD
C6			1 st choice or bandages		Until healing
After procedures		If possible	1 st choice	If necessary	Variable
	<i>Venous thromboembolism</i>				
Prevention Therapy	1 st choice		1 st choice or bandages	If necessary	At risk 4 wks
	<i>Post-thrombotic syndrome</i>				
Prevention Therapy		1 st choice If possible	If necessary 1 st choice	If necessary	>1 y after DVT Indefinite

Adapted from Partsch, H. Evidence-based compression therapy. VASA 2003;32(Suppl 63).²⁰

oxygen and nutrient diffusion to the skin and subcutaneous tissues. Finally, cytokines, such as vascular endothelial growth factor (VEGF) and tumor necrosis factor- α (TNF- α), have been demonstrated to decrease with compression therapy and this correlated with healing of the ulcer.¹⁸

Gradient elastic compression stockings are the most commonly utilized compression devices. They are available in various compositions, strengths, and lengths, and may be customized as necessary. For ulcers situated behind the inner ankle or over flat parts of the leg, pads may be used to increase local pressure.

Most compression hosiery manufacturers provide a pressure range (mm Hg) based on in vitro measurements, which may differ between manufacturers, and are not strictly comparable.¹⁹ Compression classes are often provided by the manufacturer as a substitute for pressure range (mm Hg). Such classes also vary according to measurement techniques and national regulations and are not comparable. Stiffness, which is defined by the increase of pressure created by an increase of the transverse stretch of the stocking, is not regularly declared by manufacturers.

Guidelines for the appropriate use of compression stockings are shown in Table I.²⁰ The role of elastic compression stockings in ulcer healing has been clearly validated.^{21,22} Among 113 patients with venous ulcers, healing occurred in 93% of those treated with 30 to 40 mm Hg below-knee elastic compression stockings. Compliance with therapy was crucial. Ulcer healing occurred in 97% of complaint patients in comparison with 55% of noncompliant patients. The mean time to achieve healing was 5 months. Ulcer recurrence was 29% at 5 years in compliant patients and 100% at 3 years in noncompliant

patients.¹⁷ The prophylactic use of compression therapy in patients with previous venous ulcers has been shown to be cost effective.²³

Elastic compression therapy also improves quality of life in CVI patients. In a prospective study, 112 patients with CVI completed a questionnaire assessing swelling, pain, skin discoloration, cosmesis, activity tolerance, depression, and sleep patterns. Patients were then treated with 30- to 40-mm Hg elastic compression stockings. There was overall improvement in symptom severity scores following 1 month of treatment. Further improvements were noted at 16 months.²²

Many patients are initially intolerant of compression over an ulcer. Patients should initially wear stockings only as long as they are easily tolerated, gradually increasing the time they are worn with the goal of wearing stockings whenever ambulating. Compliance may also be improved by initially fitting patients with lower-pressure stockings and progressing to higher-strength stockings. Commercial devices, such as silk inner toe liners, zippered stockings, and metal fitting aids, are available to assist in the application of elastic stockings.

Non-elastic or short stretch material may provide some hemodynamic benefits over compression stockings. High interface pressure compression narrows the veins even in the standing position, and rigid, non-elastic or short stretch material is able to intermittently occlude the veins during muscle systole, reducing ambulatory venous pressure.²⁴ Elastic compression stockings, which may have much lower resting pressures and give way during muscle contraction, cannot achieve these effects. Non-yielding materials have effects similar to intermittent pneumatic compression dur-

ing walking, particularly the endothelial release of anti-inflammatory, anticoagulant, and vasoactive mediators.²⁵ These effects may account for the improved healing rates attributed to multilayer high-pressure bandages.¹⁰

Unna's boot is a compression bandage that has been historically used to treat venous ulcers. The Unna boot is classically a three-layer dressing, requiring application by trained personnel. A rolled gauze bandage impregnated with calamine, zinc oxide, glycerin, sorbitol, gelatin, and magnesium aluminum silicate is first applied with graded compression from the forefoot to just below the knee. A 4-inch-wide continuous gauze dressing is then applied, followed by an outer elastic wrap, applied with graded compression. Rigidity of the bandage after drying may aid in decreasing edema. Unna boots are changed weekly; sooner if there is excessive ulcer drainage. The bandage requires minimal patient involvement and provides continuous compression and topical therapy. Potential disadvantages are that it can be labor intensive, the degree of compression is operator-dependent, the bandage may be uncomfortable, and the ulcer cannot be monitored. Patients may also occasionally develop a contact dermatitis requiring discontinuation of therapy. However, the technique is effective in achieving ulcer healing. In a 15-year review of 998 patients with one or more venous ulcers treated with Unna's dressings, 73% of ulcers healed in patients who returned for more than one treatment. The median time to healing for individual ulcers was 9 weeks.²⁶

Other forms of ambulatory compression include multilayered dressings and compressive orthoses.²⁷ Potential advantages of multilayered dressings include maintenance of compression for a longer period of time, more even distribution of compression, and better absorption of wound exudate. However, the efficacy of multilayered dressings still depends on application technique. A commercially available leg orthosis, consisting of multiple adjustable loop-and-hook closure compression bands, provides compression similar to Unna's boot and can be applied daily by the patient.²⁷ In comparison with elastic bandages, at least one recent study²⁸ demonstrated superior ulcer healing with such devices.

Intermittent pneumatic compression pumps may also be a useful adjunct in ulcer healing.^{29,30} Such supplementary compression may be especially useful in patients with restricted walking ability and in those with an arterial component to their ulcer. It is well established that venous blood flow velocities are increased with intermittent pneumatic compression (IPC). In addition to the physical stimulation of venous return,^{31,32} hematological and endothelial cell stimulation has been documented. Increased endogenous fibrinolysis,³³ reduced intravascular coagulation,³⁴ and stimulation of at least three forms of nitric oxide synthase (eNOS, iNOS, and nNOS) has been demonstrated.^{35,36} Increased shear stress is likely responsible for most of these biomarker changes.²⁵

Wound dressings, skin substitutes and other adjuvants to compression

Practice guidelines have recommended that simple nonadherent wound dressing combined with compression bandages be used in treating chronic venous ulcers.³⁷ However, more complex or "modern dressings" have been developed and recommended by some. These include both the semi-occlusive and biologic dressings. The degree of water vapor transmission distinguishes nonocclusive from semi-occlusive dressings. Winter³⁸ has shown that dressings promoting a moist, warm healing environment (semi-occlusive wounds), had a 40% increased epithelialization rate in comparison with nonocclusive dressings.

Semi-occlusive dressings vary in their ability to reduce water vapor transmission and other desirable characteristics.³⁹ Film dressings, composed of transparent, adherent polyurethane, protect and insulate the wound while promoting autolytic debridement of the eschar. Since this dressing type does not absorb wound drainage, maceration of the surrounding skin can occur. Hydrocolloid dressings have a water impermeable outer layer of polyurethane and an inner hydrocolloid layer that both debrides and protects the wound, while facilitating absorption of wound drainage. Semitransparent and nonadherent hydrogel dressings are usually provided in sheets and contain insoluble polymers that absorb water. Foam dressings can absorb significant quantities of exudate from the wound and are composed of silastic or polyurethane foam. Finally, alginate dressings (eg, sodium alginate) possess the maximal capacity of this dressing class for handling copious wound drainage.

The second major class of modern wound dressings has been termed biologic, because they either directly provide growth factors or indirectly stimulate growth factors within the wound (growth factor group) and accelerate healing. "Bioengineered" skin ranges in composition from acellular to living skin substitutes. Skin substitutes not only provide wound coverage, but also promote wound healing by growth factors. Apligraf is a commercially available, bilayered living skin construct that closely approximates human skin. It contains a stratum corneum and an epidermis with keratinocytes overlying a dermis of fibroblasts in a collagen matrix. It is supplied as a disk of living tissue on a gel medium and must be used within 5 days of release from the manufacturer.⁴⁰ How skin substitutes aid in healing venous ulcers is uncertain, although it is likely that they are delivery vehicles for important growth factors.

Evaluation of adjuvants to compression. Despite arguments for or against such an approach, the advantages of "modern dressings" should be proven in randomized clinical trials (RCTs), where the risk of error is low and the statistical strength is great. Level I RCTs not only provide scientific validation of a treatment option, but also strongly influence reimbursement by Center for Medicare and Medicaid Services (CMS) and other third party payors. Two previous major systematic reviews, completing their review period in 1997, concluded that "methodological weak-

Table II. Dressing trials showing statistically improved ulcer healing

<i>Dressing type</i>	<i>Patients (N) and sites</i>	<i>Control dressing (% healed)</i>	<i>Experimental dressing (% healed)</i>	<i>Study length (wks)</i>
Semi-occlusive Stacey ⁴²	113 Single site	Zincoxide Paste bandage 79%	Calcium alginate 56% Zincoxide stockinette (59%)	36
Limova ⁴³	31 2 sites	Tegasorb 5%	DuoDerm 15%	8
Growth factor DaCosta ⁴⁴	60	Placebo inj. gauze 19%	Perilesional injection of GMS stimulating factor 57%	13
Mostow ⁴⁵	120 12 sites	Allevyn 34%	Porcine collagen S I S 55%	12
Human skin equivalent Falanga ⁴⁶	309 Multicenter	Tegapore 48%	Apligraf 63%	24

nesses” marred interpretation of the relevant RCTs. In particular, they found no difference over standard control dressings for hydrocolloids, foam/films, and finally some of the “modern” dressings.

As part of a Federal agency-sponsored assessment of wound care, all RCTs on wound care published between 1997 and September 2005 were recently reviewed.³⁹ Med Line and CINAHL search engines were used to identify 68 RCTs of dressings for venous ulcers. Two successive screens were applied to select the final group of RCTs subject to analysis: (1) elastic compression, as well as other modalities of customary care, should be used in both arms of the RCT and (2) outcomes should be objective and specifically detail the proportion of wounds healed and the healing rate. Thirty-three RCTs remained for analysis of valid outcomes after the first screen. Thirteen more trials were subsequently eliminated, leaving 20 RCTs (29% of the original) for final analysis.⁴¹ The 20 RCTs were analyzed for several essential characteristics, many of which had been recommended in an FDA document on wound care studies. A priori calculation of sample size (40%), blinding of observers (35%), and outcome analysis by intention to treat (30%) was observed in a low proportion of the studies. In contrast, the majority employed baseline comparability, as demonstrated by similar wound duration and area in the control and experimental groups. The 20 RCTs were divided into three groups based on the type of wound dressing used in the experimental arm: (1) semi-occlusive dressings (SOD) – eight studies, (2) growth factors (GF) – seven studies, and (3) human skin equivalent (HSE) – five studies.

In over 50% of the RCTs, the wound was routinely debrided, which has been shown to be an independent factor promoting venous ulcer healing.³⁹ While only 15% of trials administered antibiotics, 52% used wound cleansing. The preponderance of the studies used high degrees of compression: four layer bandages were the most common form of compression (7/20, 35%); studies using short stretch bandages and class III stockings were comparable in number (4/20, 20%).

In comparison with controls, five of the 20 RCTs (25%) showed a statistically significant improvement in the proportion of ulcers healed in the experimental group (Table II). Stacey⁴² showed that wound healing rates with Viscopaste (79%), a zinc oxide impregnated bandage, were superior to either a zinc oxide impregnated stockingette (59%) or a calcium alginate fiber dressing (56%). Over an 8-week period, Limova⁴³ reported 59% of wounds healed with Tegasorb in comparison with 15% treated with DuoDerm, another hydrocolloid. Absorption of exudate and patient comfort was also superior in the Tegasorb group. Among the three growth factor studies, only one complex treatment regimen, using granulocyte macrophage stimulating factor (GMSF) administered by peri-ulcer injection⁴⁴ was associated with significantly improved healing rates in comparison with the control group (57% vs 19%). Although improved wound healing with calcitonin vasoactive intestinal peptide³⁴ has been claimed, re-evaluation of the data by others failed to demonstrate statistical superiority over Vaseline gauze. (personal communication, Thomas F. O'Donnell, MD) Mostow⁴⁵ compared collagen derived from porcine small intestinal submucosa (Oasis) with the semi-occlusive dressing, Allevyn. Wounds healed in 55% of the Oasis group in comparison with 34% in the Allevyn group. Finally, Falanga⁴⁶ conducted a multicenter trial with 309 participants treated over a much longer period of 6 months. Using a complex application schedule wherein five applications of Apligraf (allogenic cultured human skin equivalent) were allowed in the first 3 weeks of the trial if less than 50% of the wound surface was covered by Apligraf, he observed a 63% healing rate in the experimental group vs a 49% healing rate in the control group (Tegapore film dressing and Unna's boot). It should be noted that only two of the trials reported ulcer recurrence during very limited follow-up and neither showed an improvement over controls.

Wound dressing types are hierarchical in their complexity of application, ability to handle wound drainage, and requirements for a special wound base. Certainly cost, proportion of wounds healed, and time to healing are other important factors in selection of a dressing. The physician should employ the wound dressing which is easiest to apply, and which is also associated with the best drainage control and reduction of pain. Although some modern dressings have an additive effect to compression in promoting wound healing, more studies are needed. It is also important to note that contact sensitivity from ointments, creams, and dressings is a common feature in leg ulcers.

Drug treatment of chronic venous insufficiency and venous ulceration

Drugs are widely used in the management of chronic venous insufficiency and venous ulceration. Unfortunately, although much has been reported regarding alterations in the microcirculation that give rise to leg ulceration,⁴⁷ the crucial steps that might be amenable to modification by pharmacotherapy remain unknown.

When appropriately applied, traditional surgical techniques and sclerotherapy work well in the management of superficial venous disease.⁴⁸ More recent techniques, such as radio-frequency ablation, endovenous laser treatment, and ultrasound guided foam sclerotherapy, may also have advantages in the management of varicose veins. There is little role for systemic drug treatment in such situations, and no drug has yet been identified that will resolve valvular incompetence. However, drugs are commonly used for some of the milder symptoms attributed to superficial venous incompetence, including aching, itching, and feelings of swelling. "Phlebotonic" drugs are commonly used in southern European countries where compression stockings are less popular.

However, there might be considerable advantage to the use of effective drug treatments in the management of deep venous incompetence. There is no widely used method of restoring competence to damaged valves. Surgical techniques for achieving this are well known but have limited efficacy and scope. As discussed above, the use of high levels of compression (45 mm Hg at the ankle) can achieve rapid ulcer healing⁴⁹ and should remain the standard treatment in patients with deep venous incompetence once superficial venous reflux has been corrected. Advances in the pharmacological treatment of venous leg ulcers have been limited and as yet, no drug has been shown to achieve the same level of healing as high levels of compression. The only oral drugs that have been shown to have efficacy are pentoxifylline and micronized purified flavonoid fraction (MPFF). However, the development of drugs that could be used as an adjuvant to compression is highly desirable.

Plant extracts, as well as a small number of synthetic drugs, have been used to address the symptoms of venous disease. This group includes hydroxyrutosides, diosmin, and herperidine, all of which are flavonoids. Aescin, a

compound present in many proprietary medications, has also been widely used.

Diosmin is poorly absorbed from the GI tract and its availability has been enhanced by micronization, a process that reduces the drug to very small particles. Laurent investigated MPFF⁵⁰ and demonstrated efficacy in reducing symptoms (aching, itching, feeling of swelling) as well as ankle edema. MPFF has been studied more recently for its effects on venous leg ulcer healing. A meta-analysis of five prospective, randomized, controlled studies included 723 patients with venous ulcers.⁵¹ Patients were treated with compression bandaging and local wound care in all cases. In two studies, MPFF was compared with placebo and in three studies MPFF was compared with standard treatment alone. At 6 months, the odds of ulcer healing was 32% better in patients treated with adjunctive MPFF than in those managed by conventional therapy alone. The primary benefit of MPFF was seen in ulcers between 5 and 10 cm² in area and in those present for 6 to 12 months. In combination with compression, MPFF may be a useful drug in countries where it is licensed. At present, it is available in some European, Asian, and South American countries but not in the United Kingdom or the United States.

Pentoxifylline has been used with moderate success in the treatment of claudication. Its mechanism of action is probably through inhibition of cytokine-mediated neutrophil activation.⁵² Its efficacy in healing venous leg ulcers has been reported in a meta-analysis of nine trials enrolling 572 adults.⁵³ Pentoxifylline plus compression is more effective than placebo plus compression (relative risk of healing with pentoxifylline 1.30). This drug is widely available and could be considered as an adjuvant to compression in patients with venous leg ulceration.

Prostaglandin E₁ is among the drugs that might influence inflammation, considered to be one of the primary mechanisms leading to leg ulceration. Prostaglandin E₁ (PGE₁) has a number of profound effects on the microcirculation, including reduction of white cell activation, platelet aggregation inhibition, small vessel vasodilatation, and reduction of vessel wall cholesterol levels. The results of a randomized, placebo-controlled, single blind study 87 patients with venous leg ulcers have recently been reported.⁵⁴ Patients were treated with compression bandaging and conventional wound management in addition to a 20-day infusion of prostaglandin E₁ analogue (Prostavasin, Schwarz Pharma, Monheim, Germany) or placebo. After 4 months, all ulcers were healed in the active treatment group but only 32 of 38 in the placebo group. Unfortunately, despite its efficacy, the requirement for intravenous infusion of the drug restricts its applicability.

A prostacyclin analogue (Iloprost, Schering, Berlin, Germany) has also been investigated for efficacy in healing venous ulcers. Although topic application had no effect on healing,⁵⁵ it is possible that an alternative route of administration might be effective.

Sulodexide, a highly purified glycosaminoglycan, has also been evaluated in the treatment of venous leg ulcers.⁵⁶ Patients (n = 235) with leg ulcers were randomized to

receive either sulodexide or placebo for 3 months, in addition to standard wound care and compression bandaging. The trial medication was given for 20 days by injection and thereafter orally. At 2 months, 35% of ulcers in the active treatment group and 21% in the placebo group had healed. This drug is not widely available and use on the basis of one positive clinical trial cannot be recommended without reservation.

A number of other drugs used in the management of leg ulcer, particularly topical or systemic antibiotics, have not shown efficacy in healing ulcers. Since leg ulcers are frequently host to a wide range of bacteria, it has been common practice to treat them with antibiotics. However, there is no evidence that the bacterial colonization, which is invariably present, has any effect on the perpetuation of the ulcer. Antibiotics are only appropriate when treating clinically apparent infection.

Similarly, trials of the anabolic steroid stanozolol have not demonstrated efficacy in leg ulcer healing. The thromboxane A2 receptor antagonist Ifetroban, a platelet antagonist, was investigated in a randomized double blind study, but no effect was found.⁵⁷ Aspirin has not been studied in such detail, but there is no reliable evidence of benefit in treating venous ulcers. Hydroxyrutosides, often used in "phlebotonic" drugs to treat venous edema, have been found to have no effect of venous leg ulcer healing.⁵⁸

A wide range of topical medications has been used in the management of venous leg ulcers. These include tissue growth factors intended to promote wound healing. No large-scale trials support the use of these drugs, although small studies have apparently found some beneficial effects. Several case series reported promising results with topical and perilesional injections of granulocyte-macrophage colony-stimulating factor (GM-CSF) and platelet derived growth factor, human keratinocyte growth factor-2, and hepatocyte growth factor have also been investigated.⁵⁹

SURGICAL TREATMENT OF CHRONIC VENOUS INSUFFICIENCY

Until 2003, the Cochrane group favored medical treatment with agents such as pentoxifylline and flavonoids over surgical treatment. However, more recent evidence suggests a significantly more important role for surgical management. The role of surgery has become more secure with the recent publication of a randomized trial comparing surgery and compression with compression alone.⁴⁸ The ESCHAR study evaluated 500 patients with ultrasound, allocating those with superficial reflux or combined superficial and deep reflux to an arm including "simple venous surgery." Although the addition of surgery did not affect 24-week healing rates, ulcer recurrence rates were reduced from 28% to 12% at 12 months. These numbers are consistent with recurrence rates after operative intervention for perforator incompetence⁶⁰ and consistent with historical results for modified interventions addressing perforator and axial incompetence.⁶¹⁻⁶⁴ Ulcer recurrence rates ranged average 9% to 10%. An analysis of independent factors

promoting recurrence has shown that venous reflux not treated by surgery is an important factor in recurrence.

Local surgical procedures

Debridement allows the removal of necrotic tissue and may promote formation of granulation tissue. Radical excision of the ulcer bed may also be considered, especially in recalcitrant, long-standing ulcers. The fibrotic suprafascial tissue, sometimes including the fascia, is excised and the defect closed by skin grafts or free flaps. Any incompetent perforators may be dissected at the same time.

Surgery to correct venous reflux

The vast majority of patients theoretically have one or more sites of proximal reflux or obstruction that could benefit from operative treatment.⁶⁵ Many of these patients can benefit from interventions directed towards an incompetent superficial venous system. Techniques for ablation of saphenous vein reflux, including high ligation with stripping, and endovenous thermal ablation are more thoroughly reviewed in the primary venous disease section of this supplement. Foam sclerotherapy is also an excellent method to obliterate incompetent segments of the large and small saphenous vein, which is frequently followed by accelerated healing of the ulcer.⁶⁶

In a randomized controlled trial, superficial venous surgery did not improve the healing rate of venous ulcers, but could significantly reduce the 12-month rate of ulcer recurrence.⁴⁸ In a subgroup analysis of this study, it was shown that superficial venous surgery might improve venous hemodynamics in legs with venous ulceration despite co-existent deep reflux.⁶⁷ Surgical correction of superficial reflux may also abolish incompetence in some calf perforators and offer protection against developing new perforator incompetence.

Deep venous valve reconstruction is performed in only a few specialized centers. Unfortunately, the results are better for primary deep venous incompetence than for post-thrombotic syndrome.⁶⁸ As discussed in the section of primary venous disorders, internal valvuloplasty is the most suitable technique for correcting primary deep venous incompetence and is associated with approximately 70% freedom from ulcer recurrence at more than 5 years follow-up.⁶⁸⁻⁷¹ In contrast, axillary vein transfer⁷² is the mainstay for reconstruction of a refluxing, post-thrombotic deep venous system in which the valves are destroyed. Actuarial ulcer healing rates have been variable, ranging from 40% to 65% at 5 years or longer. However, in the absence of suitable alternatives, these are nevertheless significant results for a salvage procedure. Although Perrin⁷⁰ noted a high incidence of partial, and occasionally total thrombosis, within a few weeks of transfer; Raju reported results similar to those in "primary" disease. Ten-year actuarial ulcer healing was >60% and patency >90% in a large series of post-thrombotic patients.⁷³

Despite appearances, axillary vein transfer is technically more difficult than internal valvuloplasty. Proctored learning is essential for proficiency and special modifications

to standard technique are necessary in post-thrombotic cases.⁷² Successful reconstruction of the entire femoral trijunction has been reported in 32 cases using one such modification.

Surprisingly, valves in the post-thrombotic syndrome are not universally destroyed. Some are preserved but become "secondarily" incompetent due to wall stasis restriction by perivenous and wall fibrosis extending some distance from the actual thrombotic segment. This may explain the well-documented observation that valves remote from the thrombotic segment may eventually become incompetent. Regardless, such secondarily incompetent valves are amenable to direct repair without resorting to axillary vein transfer. Preoperative identification of secondarily incompetent valves by contrast venography or duplex is unreliable. Initial adventitial dissection to expose the valve attachment lines on the mural surface is an essential first step in all valvuloplasty techniques. However, very careful dissection of the thicker post-thrombotic adventitia is required to determine whether a direct repair is feasible. The presence of the lines in their entirety indicates a repairable valve; their absence suggests the need for axillary vein transfer. Venotomy is not required and time need not be wasted in a futile search for nonexistent valve cusps.⁶⁹⁻⁸³

Eriksson⁷⁵ pointed out the importance of profunda repair in post-thrombotic patients. The femoral vein is totally occluded with corresponding dilation of the profunda femoris vein in approximately 10% of post-thrombotic patients. The course and caliber of the profunda collateral may be so close to normal anatomy that it can be easily missed. The profunda valve apparatus is dilated, incompetent, and may be associated with recalcitrant ulcers. The valve is amenable to direct valvuloplasty with excellent long-term results.

Surgery to correct perforating vein incompetence

Despite evidence that surgically uncorrected venous reflux is an important factor in recurrence,⁸⁴ the role of procedures addressing perforator incompetence remains controversial. Surgery of incompetent perforators has demonstrated promising results, especially in cases with intact deep veins.⁶⁷ However, there remain concerns that new incompetent perforators continue to develop over time. Most reports have not consistently used the most recent iteration of CEAP⁸ to evaluate initial disease severity, the extent of disordered anatomy and physiology, and outcomes after the diverse interventions available to treat perforator incompetence. Randomized controlled trials will ultimately be needed to clarify the role of perforator surgery in the management of venous leg ulcers.

The surgical options for treating incompetent perforating veins include open subfascial interruptions; the rarely used classic Linton approach; subfascial endoscopic perforator surgery (SEPS) with or without axial vein ablation; extrafascial perforator interruptions including extrafascial spot ligations; and shearing procedures for distal venous ulcers. These procedures are sometimes used in combina-

tion. There have also been promising reports using foam sclerotherapy in the treatment of incompetent perforating veins. The use of foam achieves an important treatment goal - local diversion of elevated venous pressure and reflux from the ulcerated area. However, the success of this approach likely depends on concurrent reduction of global reflux and sustained venous hypertension through proximal surgical procedures. In a retrospective study of 116 patients treated with foam sclerotherapy,⁶⁶ ulcers healed in 83% of patients after 6 months. Bergan⁸⁵ has summarized the sclerotherapy results in class 4-6 disease and proposed guidelines for the use of sclerosants in the United States. These methods require careful prospective study as well.

MANAGEMENT OF CHRONIC VENOUS OBSTRUCTION

Clinical presentation

Iliac venous outflow obstruction appears to play a more important role in chronic venous insufficiency than previously understood.⁷⁹ Obstruction of the ilio caval venous segment, the common path for the lower extremity venous outflow, appears to be more symptomatic than more distal segmental occlusions. Patients with venous occlusion have leg swelling and experience exercise-induced pain in the thigh, and occasionally the calf muscles. Such venous claudication is described as a "bursting" pain that is relieved by rest and elevation of the legs. A syndrome of spinal claudication, due to spinal compression by venous collaterals, has also been rarely described. Significant deep venous obstruction causes distended varicose veins even in the supine patient; suprapubic and abdominal wall collaterals also develop in patients with pelvic venous occlusion. Bleeding from high-pressure varicosities is not infrequent and venous congestion occasionally results in hyperhidrosis and significant fluid loss through the skin. Obstruction following acute deep venous thrombosis is frequently associated with distal post-thrombotic venous valvular incompetence, leading to skin changes and venous ulceration.

Etiology and clinical importance of venous obstruction

Obstruction is most commonly due to absent or poor recanalization following an episode of acute deep venous thrombosis (DVT). Only 20% to 30% of iliac vein thrombi completely recanalize with anticoagulation alone, while the remaining veins develop obstruction with variable collateralization.^{86,87} Obstruction occurs in association with reflux in 55% of symptomatic patients and this combination leads to the higher ambulatory venous pressures and more severe symptoms than either condition alone. Obstruction is the principal cause of symptoms in approximately one-third of post-thrombotic limbs.^{87,88}

The importance and frequency of "primary," non-thrombotic iliac vein obstruction (May-Thurner syndrome or iliac vein compression syndrome) is less commonly appreciated.⁸⁹⁻⁹¹ Among more than 1000 obstructive limbs

treated for ilio caval obstruction over the last decade, approximately 40% had non-thrombotic occlusion (defined by an absent history of DVT and no venographic or ultrasound findings indicating previous DVT). Obstruction typically is due to compression, sometimes with intraluminal band or web formation, at the point where the right common iliac artery crosses the proximal left common iliac vein.⁹² Although this lesion is classically reported in the left iliac vein in young females, it is not uncommon in elderly patients and males and may also involve the right limb. Compression involves both the common and external iliac veins in at least 15% of patients.⁹³ Other have reported that intraluminal iliac vein lesions and external compression may be present in 14-30% and 88%, of the general population, respectively.^{91,94} The incidence is probably higher in symptomatic patients. One may speculate that such lesions are clinically silent until other components of the venous circulation fail and the extremity becomes decompensated.

The possibility that limbs with "primary", non-thrombotic disease had an isolated, subclinical iliac vein thrombosis initiated at the vessel crossing that propagated distally into the external iliac vein cannot be excluded. On the other hand, limbs with obvious post-thrombotic disease may have had an underlying iliac vein compression leading to iliofemoral vein thrombosis. It has also been shown that recanalization after acute iliofemoral DVT is worse when an external compression is present.⁹⁵ Regardless of the underlying events, it is clear that patients complaining of leg pain and swelling and without a history of DVT or other venous disease may have isolated iliac vein obstruction.

Less common causes of chronic ilio caval obstruction include benign or malignant tumors, retroperitoneal fibrosis, iatrogenic injury, irradiation, cysts, and aneurysms. Signs and symptoms of an underlying malignancy (weight loss, malaise, fatigue, low grade fever) or retroperitoneal fibrosis (low back pain, hydronephrosis) should be sought in patients presenting with iliofemoral venous obstruction.

Diagnosis and selection of patients

The investigation of the patients with suspected venous obstruction begins with a thorough history and physical examination followed by detailed lower extremity venous duplex scanning evaluating both obstruction and valvular incompetence. Thrombophilic states should be excluded in all patients with a previous episode of DVT. Pelvic imaging studies (computed tomography or magnetic resonance imaging) should be obtained to exclude malignancy, benign tumors, retroperitoneal fibrosis, and other etiologies. Computed tomography can also confirm compression of the left iliac vein by the overlying right common iliac artery (May-Thurner syndrome). Venous functional studies, such as air or strain gauge plethysmography, may establish the presence of outflow obstruction and aids in assessing post-operative improvement. Ascending contrast venography, with direct venous pressure measurements, will delineate the anatomy and despite the absence of a uniform definition, can suggest a hemodynamically significant obstruction.

In the absence of reflux, ambulatory venous pressure measurements are usually normal, although a resting arm-foot pressure differential of 5 mmHg or greater is considered evidence for significant obstruction. For purposes of provocative testing, exercise consists of 10 dorsiflexions of the ankles or 20 isometric contractions of the calf.

Unfortunately, the definition of hemodynamically significant venous stenosis remains obscure and there are no reliable tests to confirm the presence of such a lesion.⁹⁶ Although tests suggesting obstruction indicate the need for further investigation, a negative test does not exclude its presence. Absence of a "gold standard" is a major obstacle in evaluating the importance of chronic outflow obstruction, selecting limbs for treatment, and evaluating outcome. At present, the diagnosis of outflow obstruction largely depends on anatomic rather than hemodynamic criteria. Ascending or antegrade transfemoral venography (optimally performed with oblique projections) is the standard method of imaging the venous outflow tract and may disclose the site of obstruction and the presence of collaterals. However, intravascular ultrasound (IVUS) is superior to venography in estimating the morphological degree and extent of iliac vein stenosis and visualizing details of intraluminal lesions.⁹⁷ Iliocaval obstruction and associated abnormalities can also be detected by magnetic resonance venography (MRV) and spiral computed tomographic (CT) venography, which may replace invasive studies in the future.^{98,99}

The appropriate diagnosis of venous obstruction requires a high degree of suspicion and a low threshold for extending investigation beyond duplex ultrasound evaluation of the lower extremity. Especially targeted patients are those with clinical features (especially pain) out of proportion to detectable pathology, patients lacking another explanation for their symptoms, and patients with previous deep venous thrombosis.

Symptomatic patients with a suspicion of obstruction, with or without collaterals on ultrasound or transfemoral venography, and/or positive invasive or noninvasive tests for outflow obstruction warrant further study.

Endovascular reconstruction for chronic iliac vein and inferior vena cava obstruction

Iliocaval venoplasty and stenting has emerged as the "method of choice" in relieving proximal iliofemoral obstruction. As discussed above, the selection of patients for treatment is hampered by the lack of objective hemodynamic tests for venous obstruction and currently must be based on clinical signs and symptoms in conjunction with anatomic investigations. However, many experts believe patients with ilio caval stenosis of more than 50% on IVUS to be candidates for intervention.¹⁰⁰

The technical details of the procedure have been previously described.¹⁰¹ Although percutaneous stenting is a minimally invasive procedure, attention to detail is important to ensure a satisfactory result. Important points of the procedure include:

Table III. Results of femoro-femoral venous bypass

Author	Year	No. of limbs	Follow-up (y)	Postoperative imaging (%)	Patency rate (%)	Clinical improvement (%)	Graft material
Palma	1960	8	up to 3	13	N/A	88	Vein
Dale	1979	48	up to 12	N/A	N/A	77	Vein
May	1981	66	N/A	N/A	73	N/A	Vein
Dale	1983	56	N/A	N/A	N/A	80	Vein
Husni	1983	85	0.5 ~ 15	N/A	70	74	Vein (n = 83) PTFE (n = 2)
Halliday	1985	47	up to 18	72	75 (5-y cumulative)	89	Vein
Danza	1991	27	N/A	N/A	N/A	81	Vein
AbuRahma	1991	24	5.5	100	75 (7-y cumulative)	63	Vein
Gruss	1997	19	N/A	N/A	71	82 overall	Vein
		32	N/A	N/A	85		PTFE
Jost	2001	18	2		Primary 77; secondary 83		Vein
		3			0		PTFE

Adopted from Glociczki P, Cho JS. Surgical treatment of chronic occlusions of the iliac veins and the inferior vena cava. In: Rutherford RB, editor. Vascular surgery, 6th edition. Philadelphia: Elsevier 2005:2303-2066.¹⁰⁸

- Stenting is recommended when there is any degree of recoil after venoplasty alone and should be considered standard.
- Ultrasound guided puncture of the ipsilateral femoral vein below the suspected obstruction should be routinely used.
- IVUS is invaluable, both as a diagnostic and therapeutic tool to direct stent placement.
- When treating stenosis close to the common iliac confluence, especially when using Wallstents, place stents well into the IVC to avoid distal migration.
- A large stent (14 to 16 mm diameter) is recommended. In contrast to arteries, most veins will tolerate extensive dilation without clinical rupture.
- The entire obstruction delineated by IVUS should be covered to decrease the risk of re-stenosis.

The mortality following endovenous stenting is nil and the morbidity is <1%. Cumulative secondary patency rates are approximately 90% at 4 to 6 years and late occlusions are rare.^{102,103} A number of patients have been followed for 5 years or more without precipitous deterioration of stent patency or clinical efficacy. However, limbs with chronic post-thrombotic disease fare significantly worse after stenting than those with non-thrombotic disease (primary, assisted-primary and secondary cumulative patency rates of 65%, 85%, and 88%, and 89%, 100% and 100% at 36 months, respectively).^{103,104} Early occlusion was more common in post-thrombotic patients with thrombophilia and extensive iliofemoral occlusion or tight, non-yielding stenoses (especially when extending below the inguinal ligament). Recanalized limbs have a secondary patency of 76% at 24 months.¹⁰⁵ In-stent restenosis of greater than 50% is infrequent and occurs more commonly in post-thrombotic than non-thrombotic limbs (23% and 4%, respectively).¹⁰⁰

Despite the absence of objective hemodynamic outcome measures, the clinical efficacy of iliofemoral venous stenting is supported by impressive relief of pain and swell-

ing and high rates of ulcer healing. Objectively documented swelling is completely relieved in approximately one-third of limbs and is significantly improved in others. About 50% of patients have complete relief of pain following stenting. Despite the presence of untreated reflux in many limbs, approximately half of ulcerated legs will heal, and stay healed for up to 2 years, following iliac vein stent placement.^{103,104} Median venous clinical severity and disability scores also significantly improve (8.5 to 2 and 2 to 0, respectively).¹⁰²

Surgical reconstruction for large vein occlusions

The success of endovascular procedures for venous obstruction has diminished the role of bypass procedures in recent years.^{106,107} Early recognition and aggressive treatment of venous obstructions with catheter directed thrombolysis, mechanical venous thrombectomy, balloon angioplasty, and stents have been effective and durable with satisfactory early and midterm results. Bypass surgery is now largely limited to stent failures, both early and late, and long total occlusions, which appear to have a poorer result.^{108,109} Patients requiring resection for malignancy also continue to require surgical reconstruction of critical veins such as the inferior and superior vena cava.¹¹⁰

Femoro-femoral venous bypass (Palma procedure). First described by Palma and Esperon, the Palma procedure remains a useful technique for venous reconstruction in patients with unilateral iliac vein obstruction who are not candidates for or who have failed previous endovascular procedures.¹⁰⁹ The operation requires a normal contralateral iliofemoral venous system to assure venous drainage.

The Palma procedure uses the contralateral great saphenous vein as a bypass conduit. As long-term outcome with the use varicose saphenous veins and veins smaller than 4 mm are poor, preoperative duplex imaging is recommended. The saphenous vein is harvested using the endoscopic technique or a few small skin incisions. After ligation and division of all tributaries, the graft is distended with heparinized papaverine

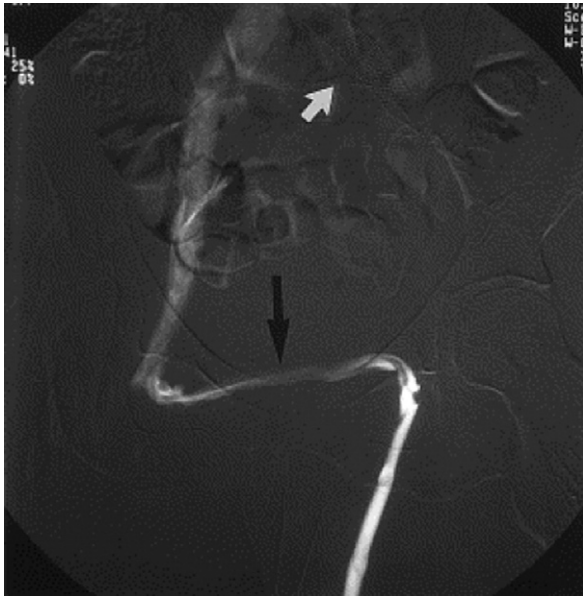

Fig 1. Venograms showing patent left to right cross-femoral saphenous vein graft 6 months after Palma procedure. From Jost CJ, Gloviczki P, Cherry KJ, McKusick MA, Harmsen WS, Jenkins GD, Bower TC. Surgical reconstructions of iliofemoral veins and the inferior vena cava for nonmalignant occlusive disease. *J Vasc Surg* 2001;33:320-8, with permission.¹⁰⁹

solution and tunneled to the contralateral groin in a suprapubic, subcutaneous position, where it is anastomosed to the common femoral vein. Excision of intraluminal post-thrombotic fibrous bands following femoral venotomy (endophlebectomy) may be needed. When suitable autologous conduit is not available, an 8 or 10-mm, externally supported expanded polytetrafluoroethylene (ePTFE) graft is the best alternative. A temporary arteriovenous fistula can be placed to improve flow and to aid patency. A large tributary of the ipsilateral great saphenous vein or the transected great saphenous vein can be anastomosed in an end-to-side fashion to the proximal superficial femoral artery. In patients with vein graft, this fistula is taken down at 3 months. In those with ePTFE grafts, the fistula should be left as long as possible in an asymptomatic patient.

Analysis of 412 operations published in nine series revealed clinical improvement in 63% to 89% of patients (Table III). Crude patency rates ranged between 70% and 85%, but follow-up periods were variable and objective graft assessment with imaging was rarely routinely performed. Results were better in patients who had regular surveillance and in those with a temporary arteriovenous fistula, with minimal distal disease, and with non-thrombotic disease (Fig 1). At least one center¹⁰⁹ reported 4-year patency rates as high as 83% for Palma grafts.

Prosthetic femorocaval or ilio caval bypass. Anatomic in-line iliac or ilio caval reconstruction can be performed for (1) unilateral disease when autologous conduit for a suprapubic graft is not available or (2) bilateral iliac,

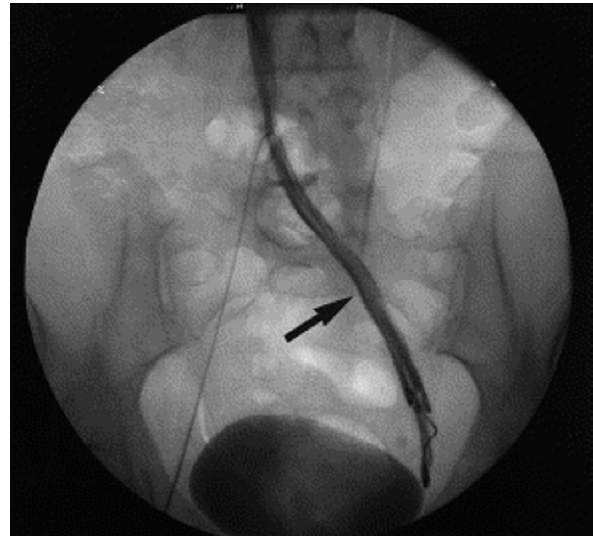


Fig 2. Patent left femorocaval PTFE bypass 11.7 years after surgery. From Jost CJ, Gloviczki P, Cherry KJ, McKusick MA, Harmsen WS, Jenkins GD, Bower TC. Surgical reconstructions of iliofemoral veins and the inferior vena cava for nonmalignant occlusive disease. *J Vasc Surg* 2001;33:320-8, with permission.¹⁰⁹

ilio caval, or inferior vena caval occlusion. In addition to failed endovascular treatment, extensive venous thrombosis (frequently following placement of a vena caval clip), tumors, and retroperitoneal fibrosis unresponsive to nonoperative therapy are potential indications.

The femoral vessels are exposed at the groin through a vertical incision, the iliac vein and the distal inferior vena cava (IVC) through oblique flank incisions. The IVC at the level of the renal veins is best exposed through a midline or a right subcostal incision. If the IVC alone is reconstructed, an externally supported 16- to 22-mm PTFE graft is appropriate. The ilio caval segment is usually reconstructed with a 14-mm graft. An arteriovenous fistula is constructed for femorocaval or long ilio caval bypasses. The fistula is maintained as long as possible, a minimum of 3 months. Life-long anticoagulation is recommended.

Experience with femorocaval and ilio caval bypass is limited, but 2-year primary and secondary patency rates of 37% and 54% have been reported^{108,109} (Fig 2). In an unpublished series of 56 patients undergoing a variety of prosthetic reconstructions for iliac vein occlusion, Sottiturai reported a 93% 1-year patency rate.

Endophlebectomy. Excision of the recanalized, organized thrombus, together with any newly formed intima, is a procedure that can be performed either alone for localized venous obstruction or combined with intraoperative iliofemoral stenting or bypass procedures. The procedure has long been combined with deep venous valve reconstructions, but it can be equally effective for venous obstruction alone. Closure of the vein is usually performed with a vein or bovine pericardial patch. Puggioni¹¹¹ re-

ported 77% of operated segments in 10 patients to be patent at 8 months. Long-term patency in a larger series of patients has not yet been reported.

Inferior vena cava reconstruction combined with excision of malignant tumors. Primary venous leiomyosarcomas or secondary tumors invading the vena cava are the most frequent indications for reconstruction. The primary tumor can involve the liver, the retroperitoneum, or the kidneys. Excellent patency of the suprarenal or infrarenal IVC can be achieved with externally supported PTFE grafts. The renal veins can also be reconstructed using short PTFE grafts. For tumors partially invading the venous wall, lateral excision and venography with or without PTFE or bovine pericardial patches are options. Patients with renal cancer frequently have floating tumor thrombus in the IVC that can be removed without circumferential reconstruction of the cava. Tumors that extend up to the right atrium need extracorporeal circulation for safe removal of the tumor thrombus.

Bower and Nagorney¹¹⁰ reported large experience with tumor resection and inferior vena cava reconstruction using PTFE grafts. Of 27 caval reconstructions, only two graft occlusions, at 7 months and 6 years, were noted. Twenty-five grafts remained patent after an average follow-up of 2 years.

Reconstruction of the superior vena cava. Surgical reconstruction is indicated in symptomatic, good risk patients with nonmalignant disease who have failed or are not candidates for endovascular treatment. Etiologies of severe superior vena cava (SVC) obstruction include mediastinal fibrosis and extensive venous thrombosis after central venous instrumentation.

A chest CT is essential to exclude an underlying tumor or mediastinal fibrosis. Bilateral arm venography provides a road map for reconstruction, while duplex scanning of the internal jugular veins is useful in assessing inflow for a central bypass.¹⁰⁷

Reconstruction is performed through a median sternotomy, with extension of the skin incision into the neck if anastomosis to the internal jugular vein is required. The central anastomosis is usually done to the SVC, if there is an adequate patent segment above the atrium, or to the right atrial appendage. Many experts consider a spiral saphenous vein graft to be the conduit of choice for SVC reconstruction, although the femoral vein is also a good conduit in selected patients. Externally supported PTFE is also suitable in this location; best results are achieved with short, large diameter grafts (12 mm to 16 mm).

Superior vena cava grafts of different types have an 80% 5-year patency rate (Fig 3). Published secondary patency rates of spiral saphenous vein grafts at 5 years are 90%.¹¹⁰ Patency rates with femoral vein and PTFE grafts have been somewhat inferior to this. Secondary procedures, such as angioplasty or stenting may be required to maintain and prolong patency. Regular follow-up with magnetic resonance, computed tomography, or contrast venography is warranted.

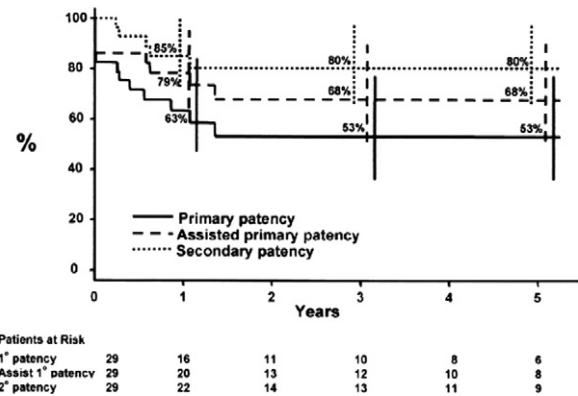


Fig 3. Patency of superior vena cava bypasses in 29 patients. From Kalra M, Gloviczki P, Andrews JC, Cherry KJ, Jr., Bower TC, Panneton JM, et al. Open surgical and endovascular treatment of superior vena cava syndrome caused by nonmalignant disease. *J Vasc Surg* 2003;38:215-23, with permission.¹⁰⁷

ARTIFICIAL VENOUS VALVES

An artificial venous valve is needed to treat chronic deep venous insufficiency (DVI) after other options have failed. The typical patient has post-thrombotic valvular insufficiency with recalcitrant or recurrent venous ulcers resistant to standard medical and surgical therapy. Options for artificial venous valves fall into two categories: Scaffolds seeking incorporation as self and scaffolds identified as self. Valve cusps made of autogenous vein are the only currently available substitutes with at least preliminary data supporting their use. Although there is clearly a clinical need, nonautogenous off-the-shelf venous valve substitutes have either failed initial clinical evaluation or remain under development.

Scaffolds seeking incorporation as self

Several approaches to construction of an artificial valve have been abandoned after discouraging results in animal studies. Among 14 fresh valved vein allografts implanted in dogs, only 7% remained patent in a 4-week study.¹¹² Similar results were obtained with bicuspid valve xenografts created from glutaraldehyde-fixed human umbilical veins supported by an aluminum mandrel.¹¹³ All 10 canine transplants thrombosed within three days. Ten canine implants of a liquid pellethane bicuspid valve supported by the same aluminum mandrel similarly thrombosed within 8 days.¹¹³

In other cases, the animal or associated studies left some hope for this approach. Platinum or pyrite-carbon covered titanium center-hinged bileaflet valves implanted in the dog femoral vein had 100% patency and competency at 3 months.¹¹⁴ However, extensive neointimal overgrowth resulted in valve failure at 2 years.¹¹⁵ It is possible that modifications could extend valve life. Allograft valve decellularization could provide a transplant devoid of donor cells. Cryopreserved, decellularized allografts implanted as arteriovenous fistulae (AVF) have functioned well and incited little antigenic response.¹¹⁶ However, use of decellularized allo-

grafts as venous valves in sheep uniformly failed within 6 weeks without anticoagulation.¹¹⁷ Despite the failure of decellularized allografts in animal models, the clinical experience suggests the need for further study. Finally, rehydrated lyophilized valved veins mechanically respond similar to native valves.¹¹⁸ Such valves can withstand greater than 350 mm Hg retrograde pressure without reflux and closure time is an acceptable 0.31 ± 0.03 seconds. This allograft remains untested in vitro as a potential venous valve substitute.

Glutaraldehyde preserved allografts supported by a distal AVF remained patent (80%) but rarely competent (25%) in a 7-week canine study.¹¹⁹ Glutaraldehyde-preserved bovine cardiac valves function well clinically and the technology exists to similarly preserve bovine venous valves of a size appropriate for human use. A glutaraldehyde-preserved bovine valve-containing vein has been percutaneously placed in a swine model. In three surviving animals, the valves remained patent and competent.¹²⁰ However, initial results from an unpublished clinical trial using a similar construct were discouraging and led to development of a streamlined design. The new design likely failed to solve clinical concerns since the parent company no longer exists.

A bioprosthetic, bicuspid stent-based venous valve has also been developed and percutaneously deployed in the external jugular vein of sheep.¹²¹ The valve is made of processed small intestinal submucosa (SIS – a collagen skeleton with growth factors) stretched over a square metal frame with a slit cut to form the valve opening. The valve is relatively resistant to thrombosis and becomes repopulated with recipient endothelial cells.^{121,122} Although patency and competency of this valve was 88%, tilting led to valve malfunction or occlusion in three animals.¹²¹ Subsequent modifications have been designed to ensure centering of the valve, improve valve hemodynamics, and prevent cusp thickening.¹²³ Development of this valve is ongoing (Cook, Inc, Bloomington, Ind) and early clinical studies are being performed outside of the United States.

A cryopreserved allograft valve utilizing standard cross matching has reached clinical trials. Despite encouraging preclinical canine studies,¹²⁴ a multicenter feasibility study suggested that low grade rejection phenomenon damaged the allogenic femoral valves yielding primary patency and competency rates of only 67% and 56%, respectively.¹²⁵ A 2-year clinical study reported a disappointing 27% patency and competency rate.¹²⁶

Cryopreserved femoral valved veins (cryovalve) are currently available (CryoLife, Inc, Kennesaw, Ga). During testing, this valve remained competent to at least 125 mm Hg of retrograde pressure. Data suggests that primary valvuloplasty may be required after thawing to ensure initial competence and this valve does fail with time.^{125,126} It may be possible to temper the rejection issues associated with this valve, but this has not been evaluated in clinical trials.

Scaffolds identified as self

Valves created by intussuscepting an autogenous vein into itself and forming a bicuspid valve with sutures 180 degrees apart have been evaluated in animal studies.^{127,128}

In experimental studies, short-term patency and competency at physiologic pressures were excellent.¹²⁷ When transplanted into the femoral vein of a canine model of chronic deep venous insufficiency, a less hemodynamically responsive valve was suggested by a modest improvement in the 90% venous refill time but not the venous filling time.¹²⁷ Investigation of a modified valve, with thinner cusps, in a canine model showed that the valve opened rapidly with minimal pressure, closed at a pressure of 3 to 5 cm of water and could withstand physiologic hydrostatic pressure without reflux.¹²⁹ However, a thin layer of thrombus formed along the cusp wall without anticoagulation, resulting in valve incompetence. Although a possible substitute valve, there remain concerns regarding optimal function and the risk of thrombosis.

Repopulating a decellularized valved vein allograft with donor smooth muscle and endothelial cells would make a transplant much like an autogenous valve. In a sheep model, the seeded allograft was transplanted into the external jugular vein of the donor. Without long-term anticoagulation, 9 of 12 seeded allograft transplants were patent and competent at 12 weeks. One transplant occluded and two valves were frozen by neointimal ingrowth.¹¹⁷ These allografts did perform much better than unseeded allografts, which universally failed; but not as well as eight autografts, which were all patent and competent.

Clinical studies have also evaluated the use of autogenous venous tissue to create venous valves. Raju reported good results in a small series of patients who underwent “de novo” valve reconstruction procedures.¹³⁰ Using autogenous vein from various locations and after trimming the adventitia and part of the media, semi-lunar cusps were fashioned and sutured into the recipient vein with the non-endothelial surface directed toward the lumen to decrease thrombotic risk.

Plagnol¹³¹ fashioned a bicuspid valve by invaginating a stump of the long saphenous vein into the femoral vein. Nineteen of 20 such reconstructions were patent and competent at a mean of 10 months. One valve demonstrated reflux because of insufficient valve length. Although a potential concern, problems with invagination of an adventitial surface into the venous lumen were not substantiated in this report. Others have reported the creation of bicuspid or monocusp valves by dissecting the intimal/medial wall of thickened post-thrombotic veins to form cusps. The initial seven cases¹³² were sufficiently successful to warrant continued study and a total of eighteen venous valves constructed in the post-thrombotic deep venous system of 16 patients with recurrent or non-healing venous ulcers have now been reported.¹³³ These patients were anticoagulated for 6 months. At an average 22 months, 83% of the valves remained primarily patent with improved duplex and air plethysmographic findings. Early thrombosis below the valve occurred in two patients and there was one late occlusion after beginning oral contraceptives. This technique appears promising but is as yet unsubstantiated by other investigators.

REFERENCES

1. Stanton JA. Aesculapius: a modern tale. *JAMA* 1999;281:476-7.
2. Sarkar PK, Ballantyne S. Management of leg ulcers. *Postgrad Med J* 2000;76:674-82.
3. Bergan JJ. Historical highlights in treating venous insufficiency. In: Bergan JJ, Yao JST, editors. *Venous disorders*. Philadelphia: W.B. Saunders Company; 1991. p. 3-18.
4. Bauer G. The etiology of leg ulcers and their treatment by resection of the popliteal vein. *J Inter Chir* 1948;8:937-67.
5. Ruckley CV. Socio-economic impact of chronic venous insufficiency and leg ulcers. *Angiology* 1997;48:67-9.
6. Kistner RL. Definitive diagnosis and definitive treatment in chronic venous disease: a concept whose time has come. *J Vasc Surg* 1996 Nov;24:703-10.
7. Mackenzie RK, Ludlam CA, Ruckley CV, Allan PL, Burns P, Bradbury AW. The prevalence of thrombophilia in patients with chronic venous leg ulceration. *J Vasc Surg* 2002;35:718-22.
8. Eklof B, Rutherford RB, Bergan JJ, Carpentier PH, Gloviczki P, Kistner RL, et al. Revision of the CEAP classification for chronic venous disorders: consensus statement. *J Vasc Surg* 2004;40:1248-52.
9. Cullum N, Nelson EA, Fletcher AW, Sheldon TA. Compression bandages and stocking for venous leg ulcers. *The Cochrane Library*. 1999;4:1-19.
10. Cullum N, Nelson EA, Fletcher AW, Sheldon TA. Compression for venous leg ulcers. *Cochrane Database Syst Rev* 2001;2:CD000265.
11. Mayberry J, Moneta G, Taylor L, Porter J. Fifteen-year results of ambulatory compression therapy for chronic venous ulcers. *Surgery* 1991;109:578-81.
12. Mayrovitz HN, Sims N. Effects of ankle-to-knee external pressures on skin blood perfusion under and distal to compression. *Adv Skin Wound Care*. 2003;16:198-202.
13. Partsch H. Improvement of venous pumping function in chronic venous insufficiency by compression depending on pressure and material. *VASA* 1984;13:58-64.
14. Partsch H, Menzinger G, Mostbeck A. Inelastic leg compression is more effective to reduce deep venous refluxes than elastic bandages. *Dermatol Surg* 1999;25:695-700.
15. Sarin S, Scurr JH, Coleridge Smith PD. Mechanism of action of external compression on venous function. *Br J Surg* 1992;79:499-502.
16. Nehler MR, Moneta GL, Woodard DM, DeFrang RD, Harker CT, Taylor LM, Jr, et al. Perimalleolar subcutaneous tissue pressure effects of elastic compression stockings. *J Vasc Surg* 1993;18:783-8.
17. Nehler MR, Porter JM. The lower extremity venous system. Part II: The pathophysiology of chronic venous insufficiency. *Perspect Vasc Surg* 1992;5:81.
18. Murphy MA, Joyce WP, Condron C, Bouchier-Hayes D. A reduction in serum cytokine levels parallels healing of venous ulcers in patients undergoing compression therapy. *Eur J Vasc Endovasc Surg* 2002;23:349-52.
19. European prestandard on compression hosiery. *Comite Europeen de Normalisation*; 2001; Brussels: ENV; 2001.
20. Partsch H. Evidence-based compression therapy. *VASA* 2003;32 (Suppl 63):36.
21. Anning S. Leg ulcers: The results of treatment. *Angiology*. 1956;7:505.
22. Motykie GD, Caprini JA, Arcelus JI, Reyna JJ, Overom E, Mokhtee D. Evaluation of therapeutic compression stockings in the treatment of chronic venous insufficiency. *Dermatol Surg* 1999;25:116-20.
23. Korn P, Patel ST, Heller JA, Deitch JS, Krishnasastri KV, Bush HL, et al. Why insurers should reimburse for compression stockings in patients with chronic venous stasis. *J Vasc Surg* 2002;35:950-7.
24. Partsch B, Partsch H. Calf compression pressure required to achieve venous closure from supine to standing positions. *J Vasc Surg* 2005;42:734-8.
25. Dai G, Tsukurov O, Orkin RW, Abbott WM, Kamm RD, Gertler JP. An in vitro cell culture system to study the influence of external pneumatic compression on endothelial function. *J Vasc Surg* 2000;32:977-87.
26. Lippmann HI, Fishman LM, Farrar RH, Bernstein RK, Zybert PA. Edema control in the management of disabling chronic venous insufficiency. *Arch Phys Med Rehabil* 1994;75:436-41.
27. Vernick SH, Shapiro D, Shaw FD. Legging orthosis for venous and lymphatic insufficiency. *Arch Phys Med Rehabil* 1987;68:459-61.
28. Blecken SR, Villavicencio JL, Kao TC. Comparison of elastic versus nonelastic compression in bilateral venous ulcers: a randomized trial. *J Vasc Surg* 2005;42:1150-5.
29. Kumar S, Samraj K, Nirujogi V, Budnik J, Walker MA. Intermittent pneumatic compression as an adjuvant therapy in venous ulcer disease. *J Tissue Viability*. 2002;12:42-4, 6, 8 passim.
30. Mani R, Vowden K, Nelson EA. Intermittent pneumatic compression for treating venous leg ulcers. *Cochrane Database Syst Rev* 2001;23:CD001899.
31. Delis KT, Azizi ZA, Stevens RJ, Wolfe JH, Nicolaides AN. Optimum intermittent pneumatic compression stimulus for lower-limb venous emptying. *Eur J Vasc Endovasc Surg* 2000;19:261-9.
32. Delis KT, Slimani G, Hafez HM, Nicolaides AN. Enhancing venous outflow in the lower limb with intermittent pneumatic compression. A comparative haemodynamic analysis on the effect of foot vs calf and calf compression. *Eur J Vasc Endovasc Surg* 2000;19:250-60.
33. Comerota AJ, Chouhan V, Harada RN, Sun L, Hosking J, Veerman-sunemi R, et al. The fibrinolytic effects of intermittent pneumatic compression: mechanism of enhanced fibrinolysis. *Ann Surg* 1997;226:306-13; discussion 13-4.
34. Chouhan VD, Comerota AJ, Sun L, Harada R, Gaughan JP, Rao AK. Inhibition of tissue factor pathway during intermittent pneumatic compression: a possible mechanism for antithrombotic effect. *Arterio-scler Thromb Vasc Biol* 1999;19:2812-7.
35. Chen LE, Liu K, Qi WN, Joneschild E, Tan X, Seaber AV, et al. Role of nitric oxide in vasodilation in upstream muscle during intermittent pneumatic compression. *J Appl Physiol* 2002;92:559-66.
36. Tan X, Qi WN, Gu X, Urbaniak JR, Chen LE. Intermittent pneumatic compression regulates expression of nitric oxide synthases in skeletal muscles. *J Biomech* 2006;39:2430-7.
37. Simon DA, Dix FP, McCollum CN. Management of venous leg ulcers. *BMJ* 2004;328:1358-62.
38. Winter GD. Formation of the scab and the rate of epithelization of superficial wounds in the skin of the young domestic pig. *Nature* 1962;193:293-4.
39. Lau J, Tatsiou E, O'Donnell TF. Usual care in the management of chronic wounds: a review of the recent literature. In: *Quality Agency for Healthcare Research*, Washington, DC, editor; 2005. p. 513-6.
40. Sibbald RG. Apligraf living skin equivalent for healing venous and chronic wounds. *J Cutan Med Surg* 1998;3(Suppl 1):S1-24-8.
41. O'Donnell TF, Jr. Venous ulcers: what really works and what does not; based on level I evidence. *Vascular* 2005;13:513-6.
42. Stacey MC, Jopp-Mckay AG, Rashid P, Hoskin SE, Thompson PJ. The influence of dressings on venous ulcer healing--a randomised trial. *Eur J Vasc Endovasc Surg* 1997;13:174-9.
43. Limova M, Troyer-Caudle J. Controlled, randomized clinical trial of 2 hydrocolloid dressings in the management of venous insufficiency ulcers. *J Vasc Nurs* 2002;20:22-32; quiz 3-4.
44. DaCosta RM, Ribeiro Jesus FM, Aniceto C, Mendes M. Randomized, double-blind, placebo-controlled, dose-ranging study of granulocyte-macrophage colony stimulating factor in patients with chronic venous leg ulcers. *Wound Rep Reg* 1999;7:17-25.
45. Mostow EN, Haraway GD, Dalsing M, Hodde JP, King D. Effectiveness of an extracellular matrix graft (OASIS Wound Matrix) in the treatment of chronic leg ulcers: a randomized clinical trial. *J Vasc Surg* 2005;41:837-43.
46. Falanga V, Margolis D, Alvarez O, Auletta M, Maggiasimo F, Altman M, et al. Rapid healing of venous ulcers and lack of clinical rejection with an allogeneic cultured human skin equivalent. *Human Skin Equivalent Investigators Group*. *Arch Dermatol* 1998;134:293-300.
47. Gschwandtner ME, Ehringer H. Microcirculation in chronic venous insufficiency. *Vasc Med* 2001;6:169-79.
48. Barwell JR, Davies CE, Deacon J, Harvey K, Minor J, Sassano A, et al. Comparison of surgery and compression with compression alone in

- chronic venous ulceration (ESCHAR study): randomised controlled trial. *Lancet* 2004;363:1854-9.
49. Moffatt CJ, Franks PJ, Oldroyd M, Bosanquet N, Brown P, Greenhalgh RM, et al. Community clinics for leg ulcers and impact on healing. *BMJ* 1992;305:1389-92.
 50. Laurent R, Gilly R, Frileux C. Clinical evaluation of a venotropic drug in man. Example of Daflon 500 mg. *Int Angiol* 1988;7:39-43.
 51. Coleridge-Smith P, Lok C, Ramelet AA. Venous leg ulcer: a meta-analysis of adjunctive therapy with micronized purified flavonoid fraction. *Eur J Vasc Endovasc Surg* 2005;30:198-208.
 52. Sullivan GW, Carper HT, Novick WJ, Jr., Mandell GL. Inhibition of the inflammatory action of interleukin-1 and tumor necrosis factor (alpha) on neutrophil function by pentoxifylline. *Infect Immun* 1988;56:1722-9.
 53. Jull AB, Waters J, Arroll B. Pentoxifylline for treating venous leg ulcers. *Cochrane Database Syst Rev* 2002;1:CD001733.
 54. Milio G, Mina C, Cospite V, Almasio PL, Novo S. Efficacy of the treatment with prostaglandin E-1 in venous ulcers of the lower limbs. *J Vasc Surg* 2005;42:304-8.
 55. Werner-Schlenzka H, Kuhlmann RK. Treatment of venous leg ulcers with topical iloprost: a placebo controlled study. *VASA* 1994;23:145-50.
 56. Coccheri S, Scondotto G, Agnelli G, Aloisi D, Palazzini E, Zamboni V. Randomised, double blind, multicentre, placebo controlled study of sulodexide in the treatment of venous leg ulcers. *Thromb Haemost* 2002;87:947-52.
 57. Lyon RT, Veith FJ, Bolton L, Machado F. Clinical benchmark for healing of chronic venous ulcers. Venous Ulcer Study Collaborators. *Am J Surg* 1998;176:172-5.
 58. Wright DD, Franks PJ, Blair SD, Backhouse CM, Moffatt C, McCollum CN. Oxerutins in the prevention of recurrence in chronic venous ulceration: randomized controlled trial. *Br J Surg* 1991;78:1269-70.
 59. de Araujo T, Valencia I, Federman DG, Kirsner RS. Managing the patient with venous ulcers. *Ann Intern Med* 2003;138:326-34.
 60. Kalra M, Gloviczki P. Surgical treatment of venous ulcers: role of subfascial endoscopic perforator vein ligation. *Surg Clin North Am* 2003;83:671-705.
 61. DePalma RG. Surgical therapy for venous stasis: results of a modified Linton operation. *Am J Surg* 1979;137:810-3.
 62. DePalma RG. Surgical treatment of chronic venous ulceration. In: Raymond-Martinbeau R, Prescott M, Summo M, editors. *Phlebology* 92. Paris: John Libby Eurotext; 1992. p. 1235-7.
 63. DePalma RG. Evolving surgical approaches to venous ulceration. *Phlebology* 1995;10(Suppl 1):980-2.
 64. DePalma RG, Kowallek DL. Venous ulceration: a cross-over study from nonoperative to operative treatment. *J Vasc Surg* 1996;24:788-92.
 65. Danielsson G, Arfvidsson B, Eklof B, Kistner RL, Masuda EM, Satoc DT. Reflux from thigh to calf, the major pathology in chronic venous ulcer disease: surgery indicated in the majority of patients. *Vasc Endovascular Surg* 2004;38:209-19.
 66. Cabrera J, Redondo P, Becerra A, Garrido C, Cabrera J, Jr., Garcia-Olmedo MA, et al. Ultrasound-guided injection of polidocanol microfoam in the management of venous leg ulcers. *Arch Dermatol* 2004;140:667-73.
 67. Gohel MS, Barwell JR, Earnshaw JJ, Heather BP, Mitchell DC, Whyman MR, et al. Randomized clinical trial of compression plus surgery versus compression alone in chronic venous ulceration (ESCHAR study)—haemodynamic and anatomical changes. *Br J Surg* 2005;92:291-7.
 68. Tripathi R, Sieunarine K, Abbas M, Durrani N. Deep venous valve reconstruction for non-healing leg ulcers: techniques and results. *ANZ J Surg* 2004;74:34-9.
 69. Masuda EM, Kistner RL. Long-term results of venous valve reconstruction: a four- to twenty-one-year follow-up. *J Vasc Surg* 1994;19:391-403.
 70. Perrin M. Reconstructive surgery for deep venous reflux: a report on 144 cases. *Cardiovasc Surg* 2000;8:246-55.
 71. Raju S, Fredericks RK, Hudson CA, Fountain T, Neglen PN, Devidas M. Venous valve station changes in "primary" and post-thrombotic reflux: an analysis of 149 cases. *Ann Vasc Surg* 2000;14:193-9.
 72. Raju S, Neglen P, Doolittle J, Meydrech EF. Axillary vein transfer in trabeculated post-thrombotic veins. *J Vasc Surg* 1999;29:1050-62; discussion 62-4.
 73. Raju S, Fredericks RK, Neglen PN, Bass JD. Durability of venous valve reconstruction techniques for "primary" and post-thrombotic reflux. *J Vasc Surg* 1996;23:357-66; discussion 66-7.
 74. Christopoulos D, Nicolaides AN, Galloway JM, Wilkinson A. Objective noninvasive evaluation of venous surgical results. *J Vasc Surg* 1988;8:683-7.
 75. Eriksson I. Reconstructive venous surgery. *Acta Chir Scand Suppl* 1988;544:69-74.
 76. Killewich LA, Bedford GR, Beach KW, Strandness DE, Jr. Spontaneous lysis of deep venous thrombi: rate and outcome. *J Vasc Surg* 1989;9:89-97.
 77. Kistner RL. Primary venous valve incompetence of the leg. *Am J Surg* 1980;140:218-24.
 78. Neglen P, Egger JF, 3rd, Olivier J, Raju S. Hemodynamic and clinical impact of ultrasound-derived venous reflux parameters. *J Vasc Surg* 2004;40:303-10.
 79. Neglen P, Thrasher TL, Raju S. Venous outflow obstruction: an underestimated contributor to chronic venous disease. *J Vasc Surg* 2003;38:879-85.
 80. Raju S, Berry MA, Neglen P. Transcommissural valvuloplasty: technique and results. *J Vasc Surg* 2000;32:969-76.
 81. Raju S, Fountain T, Neglen P, Devidas M. Axial transformation of the profunda femoris vein. *J Vasc Surg* 1998;27:651-9.
 82. Raju S, Neglen PJ, Carr-White PA, Fredericks RK, Devidas M. Ambulatory venous hypertension: component analysis in 373 limbs. *Vasc Surg* 1999;33:257-67.
 83. Sottiurai VS. Surgical correction of recurrent venous ulcer. *J Cardiovasc Surg (Torino)* 1991;32:104-9.
 84. Gohel MS, Taylor M, Earnshaw JJ, Heather BP, Poskitt KR, Whyman MR. Risk factors for delayed healing and recurrence of chronic venous leg ulcers—an analysis of 1324 legs. *Eur J Vasc Endovasc Surg* 2005;29:74-7.
 85. Bergan JJ, Pascarella L. Severe chronic venous insufficiency: primary treatment with sclerofoam. *Semin Vasc Surg* 2005;18:49-56.
 86. Akesson H, Brudin L, Dahlstrom JA, Eklof B, Ohlin P, Plate G. Venous function assessed during a 5-year period after acute iliofemoral venous thrombosis treated with anticoagulation. *Eur J Vasc Surg* 1990;4:43-8.
 87. Johnson BF, Manzo RA, Bergelin RO, Strandness DE. Relationship between changes in the deep venous system and the development of the postthrombotic syndrome after an acute episode of lower limb deep vein thrombosis: a one- to six- year follow-up. *J Vasc Surg* 1995;21:307-13.
 88. Johnson BF, Manzo RA, Bergelin RO, Strandness DE. The site of residual abnormalities in the leg veins in long-term follow-up after deep venous thrombosis and their relationship to the development of the post-thrombotic syndrome. *Int Angiol* 1996;15:14-9.
 89. May R, Thurner J. Ein gefäßsporn in der V. iliaca comm. sin. als wahrscheinliche Ursache der überwiegend linksseitigen Beckenvenenthrombose. *Z Kreislaufforsch.* 1956;45:912-17.
 90. Raju S, Neglen P. High prevalence of nonthrombotic iliac vein lesions in chronic venous disease: a permissive role in pathogenicity. *J Vasc Surg* 2006;44:136-43; discussion 44.
 91. Cockett FB, Thomas ML. The iliac compression syndrome. *Br J Surg* 1965;52:816-21.
 92. Negus D, Fletcher EW, Cockett FB, Thomas ML. Compression and band formation at the mouth of the left common iliac vein. *Br J Surg* 1968;55:369-74.
 93. Neglen P, Berry MA, Raju S. Endovascular surgery in the treatment of chronic primary and post-thrombotic iliac vein obstruction. *Eur J Vasc Endovasc Surg* 2000;20:560-71.
 94. Erich WE, Krumbhaar EB. A frequent obstructive anomaly of the mouth of the left common iliac vein. *Am Heart J* 1943;26:737-50.

95. Fraser DG, Moody AR, Morgan PS, Martel A. Iliac compression syndrome and recanalization of femoropopliteal and iliac venous thrombosis: a prospective study with magnetic resonance venography. *J Vasc Surg* 2004;40:612-9.
96. Neglen P, Raju S. Proximal lower extremity chronic venous outflow obstruction: recognition and treatment. *Semin Vasc Surg* 2002;15:57-64.
97. Neglen P, Raju S. Intravascular ultrasound scan evaluation of the obstructed vein. *J Vasc Surg* 2002;35:694-700.
98. Chung JW, Yoon CJ, Jung SI, Kim HC, Lee W, Kim YI, et al. Acute iliofemoral deep vein thrombosis: evaluation of underlying anatomic abnormalities by spiral CT venography. *J Vasc Interv Radiol* 2004;15:249-56.
99. Fraser DG, Moody AR, Martel A, Morgan PS. Re-evaluation of iliac compression syndrome using magnetic resonance imaging in patients with acute deep venous thromboses. *J Vasc Surg* 2004;40:604-11.
100. Neglen P, Raju S. In-stent recurrent stenosis in stents placed in the lower extremity venous outflow tract. *J Vasc Surg* 2004;39:181-7.
101. Neglen P, Raju S. Endovascular treatment of chronic occlusions of the iliac veins and the inferior vena cava. In: Rutherford RB, editor. *Vascular surgery*. 6th ed. Philadelphia: Elsevier Saunders; 2005. p. 2321-32.
102. Hartung O, Otero A, Boufi M, Decaridi G, Barthelemy P, Juhan C, et al. Midterm results of endovascular treatment for symptomatic chronic nonmalignant ilio caval venous occlusive disease. *J Vasc Surg* 2005;42:1138-44; discussion 44.
103. Neglen P. Endovascular treatment of chronic iliofemoral venous obstruction - a review. *Phlebology* 2003;43:204-11.
104. Raju S, Owen S, Jr., Neglen P. The clinical impact of iliac venous stents in the management of chronic venous insufficiency. *J Vasc Surg* 2002;35:8-15.
105. Raju S, McAllister S, Neglen P. Recanalization of totally occluded iliac and adjacent venous segments. *J Vasc Surg* 2002;36:903-11.
106. Gloviczki P, Delis KT, Bjarnason H. Endovascular treatment for major vein occlusion. In: Pearce WH, Matsumura JS, Yao JST, editors. *Trends in vascular surgery*. Evanston, (IL): Greenwood Academic; 2005. p. 229-41.
107. Kalra M, Gloviczki P, Andrews JC, Cherry KJ, Jr, Bower TC, Panneton JM, et al. Open surgical and endovascular treatment of superior vena cava syndrome caused by nonmalignant disease. *J Vasc Surg* 2003;38:215-23.
108. Gloviczki P, Cho JS. Surgical treatment of chronic occlusions of the ilio caval veins. In: Rutherford RB, editor. *Rutherford's Vascular Surgery*. 6th ed. Philadelphia: Elsevier; 2005. p. 2303-20.
109. Jost CJ, Gloviczki P, Cherry KJ, Jr., McKusick MA, Harmsen WS, Jenkins GD, et al. Surgical reconstruction of iliofemoral veins and the inferior vena cava for nonmalignant occlusive disease. *J Vasc Surg* 2001;33:320-7; discussion 7-8.
110. Bower TC, Nagorney DM, Cherry KJ, Jr, Toomey BJ, Hallett JW, Panneton JM, et al. Replacement of the inferior vena cava for malignancy: an update. *J Vasc Surg* 2000;31:270-81.
111. Puggioni A, Kistner RL, Eklof B, Lurie F. Surgical disobliteration of postthrombotic deep veins—endophlebectomy—is feasible. *J Vasc Surg* 2004;39:1048-52.
112. McLachlin AD, Carroll SE, Meads GE, Amacher AL. Valve replacement in the recanalized incompetent superficial femoral vein in dogs. *Ann Surg* 1965;162:446-52.
113. Hill R, Schmidt S, Evancho M, Hunter T, Hillegass D, Sharp W. Development of a prosthetic venous valve. *J Biomed Mater Res* 1985;19:827-32.
114. Taheri SA, Rigan D, Wels P, Mentzer R, Shores RM. Experimental prosthetic vein valve. *Am J Surg* 1988;156:111-4.
115. Taheri SA, Schultz RO. Experimental prosthetic vein valve. Long-term results. *Angiology* 1995;46:299-303.
116. Madden R, Lipkowitz G, Benedetto B, Kurbanov A, Miller M, Bow L. Decellularized cadaver vein allografts used for hemodialysis access do not cause allosensitization or preclude kidney transplantation. *Am J Kidney Dis* 2002;40:1240-3.
117. Teebken OE, Puschmann C, Aper T, Haverich A, Mertsching H. Tissue-engineered bioprosthetic venous valve: a long-term study in sheep. *Eur J Vasc Endovasc Surg* 2003;25:305-12.
118. Reeves TR, Cezeaux JL, Sackman JE, Cassada DC, Freeman MB, Stevens SL, et al. Mechanical characteristics of lyophilized human saphenous vein valves. *J Vasc Surg* 1997;26:823-8.
119. Kaya M, Grogan JB, Lentz D, Tew W, Raju S. Glutaraldehyde-preserved venous valve transplantation in the dog. *J Surg Res* 1988;45:294-7.
120. Gomez-Jorge J, Venbrux AC, Magee C. Percutaneous deployment of a valved bovine jugular vein in the swine venous system: a potential treatment for venous insufficiency. *J Vasc Interv Radiol* 2000;11:931-6.
121. Pavcnik D, Uchida BT, Timmermans HA, Corless CL, O'Hara M, Toyota N, et al. Percutaneous bioprosthetic venous valve: a long-term study in sheep. *J Vasc Surg* 2002;35:598-602.
122. Broutzos E, Pavcnik D, Timmermans HA, Corless C, Uchida BT, Nihsen ES, et al. Remodeling of suspended small intestinal submucosa venous valve: an experimental study in sheep to assess the host cells' origin. *J Vasc Interv Radiol* 2003;14:349-56.
123. Pavcnik D, Kaufman J, Uchida B, Correa L, Hiraki T, Kyu SC, et al. Second-generation percutaneous bioprosthetic valve: a short-term study in sheep. *J Vasc Surg* 2004;40:1223-7.
124. Burkhart HM, Fath SW, Dalsing MC, Sawchuk AP, Cikrit DF, Lalka SG. Experimental repair of venous valvular insufficiency using a cryopreserved venous valve allograft aided by a distal arteriovenous fistula. *J Vasc Surg* 1997;26:817-22.
125. Dalsing MC, Raju S, Wakefield TW, Taheri S. A multicenter, phase I evaluation of cryopreserved venous valve allografts for the treatment of chronic deep venous insufficiency. *J Vasc Surg* 1999;30:854-64.
126. Neglen P, Raju S. Venous reflux repair with cryopreserved vein valves. *J Vasc Surg* 2003;37:552-7.
127. Dalsing MC, Lalka SG, Unthank JL, Grieshop RJ, Nixon C, Davis T. Venous valvular insufficiency: influence of a single venous valve (native and experimental). *J Vasc Surg* 1991;14:576-87.
128. Wilson NM, Rutt DL, Browne NL. In situ venous valve construction. *Br J Surg* 1991;78:595-600.
129. Rosenbloom MS, Schuler JJ, Bishara RA, Ronan SG, Flanigan DP. Early experimental experience with a surgically created, totally autogenous venous valve: a preliminary report. *J Vasc Surg* 1988;7:642-6.
130. Raju S, Hardy JD. Technical options in venous valve reconstruction. *Am J Surg* 1997;173:301-7.
131. Plagnol P, Ciostek P, Grimaud JP, Prokopowicz SC. Autogenous valve reconstruction technique for post-thrombotic reflux. *Ann Vasc Surg* 1999;13:339-42.
132. Maleti O. Venous valvular reconstruction in post-thrombotic syndrome. A new technique. *Journal des Maladies Vasculaires* 2002;27:218-21.
133. Lugal M, Maleti O. Neovalve construction in post-thrombotic syndrome. American Venous Forum, 17th Annual Meeting; 2005; San Diego, CA; 2005.

Submitted Sep 28, 2006; accepted Aug 19, 2007.